

## Vertebral column malformations in New Zealand delphinids with a review of cases world wide

J. Berghan<sup>1</sup> and I. N. Visser<sup>2</sup>

<sup>1</sup>117 Te Haumi Drive, Paihia, Bay of Islands, Northland, New Zealand

<sup>2</sup>The Orca Project, 'Aorangi', Matapouri Road, R.D 3, Whangarei, Northland, New Zealand

### Abstract

Few detailed reports of vertebral column malformations in cetaceans have been published. This manuscript documents vertebral column malformation in ten wild delphinids (six bottlenose dolphins, two killer whales, and two Hector's dolphins) sighted in New Zealand waters. Three cases show scoliosis, three show kyphoscoliosis, two show kyphosis, one shows lordosis, and one case shows a slight lateral malformation. Previously documented cases of vertebral column malformations in cetaceans are listed, and further unpublished reports from around the world are presented in a table. The pathogenesis of vertebral column malformations in cetaceans are discussed.

Key words: vertebral column malformation, scoliosis, kyphosis, kyphoscoliosis, lordosis, bottlenose dolphin, killer whale, Hector's dolphin.

### Introduction

Anatomical malformation can be defined as any deviation from normal formation, and has varying degrees of prominence. Malformation of the vertebral column may be outwardly conspicuous in the form of scoliosis (lateral curvature of the vertebral column; Wise *et al.*, 1997), kyphosis (increased convexity in the curvature of the vertebral column as viewed from the side; Wise *et al.*, 1997), lordosis (anterior concavity in the curvature of the vertebral column as viewed from the side; Wise *et al.*, 1997), kyphoscoliosis (backward and lateral curvature of the vertebral column; Miller & Brackman Keane, 1983), or lordoscoliosis (lordosis complicated with scoliosis; Miller & Brackman Keane, 1983). Other malformations, e.g., anomalies in vertebra structure, may only become apparent upon necropsy (e.g., Dixon, 1984; Kompanje, 1995a).

Few detailed cases of conspicuous vertebral column malformations in cetaceans, describing the pathology, have been reported (bottlenose dolphin,

*Tursiops truncatus*, Alexander *et al.*, 1989; white-beaked dolphin, *Lagenorhynchus albirostris*, Kompanje, 1995b; Risso's dolphin, *Grampus griseus*, Nutman & Kirk, 1988; Bortolotto, 1996; and tucuxi, *Sotalia fluviatilis*, Fragoso, 1998). Beyond these examples, the majority of accounts are primarily anecdotal (bottlenose dolphin, Lilley, 1962; Williams, 1992; Wells & Scott, 1997; Wilson *et al.*, 1997; common dolphin, *Delphinus delphis*, Clokie & Kobus, 1990; Hector's dolphin, *Cephalorhynchus hectori*, Dawson & Slooten, 1996; beluga whale, *Delphinapterus leucas*, Johnston & McCrea, 1992; sperm whale, *Physeter macrocephalus*, Berzin, 1971; humpback whale, *Megaptera novaeangliae*, Osmond & Kaufman, 1998; and a fin whale fetus, *Balaenoptera physalus*, Slijper, 1949).

### Materials and Methods

We report on six bottlenose dolphins, two Hector's dolphins, and two killer whales, *Orcinus orca*, sighted in New Zealand waters, each showing visually detectable attributes of mild to severe vertebral column malformation. Data and photographs were collected opportunistically over a 6-yr period (1994–1999), during the course of other field work. In addition, we list unpublished reports of similarly malformed delphinids from around the world (Table 1), which were gathered by posting a request for information on the e-mail discussion list, MARMAM (Marine Mammals Research and Conservation), in 1996. A standardized questionnaire was mailed to respondents, and only those that provided a detailed account of vertebral column malformation were included, resulting in a further 11 cases (six bottlenose dolphins, one common dolphin, and four killer whales).

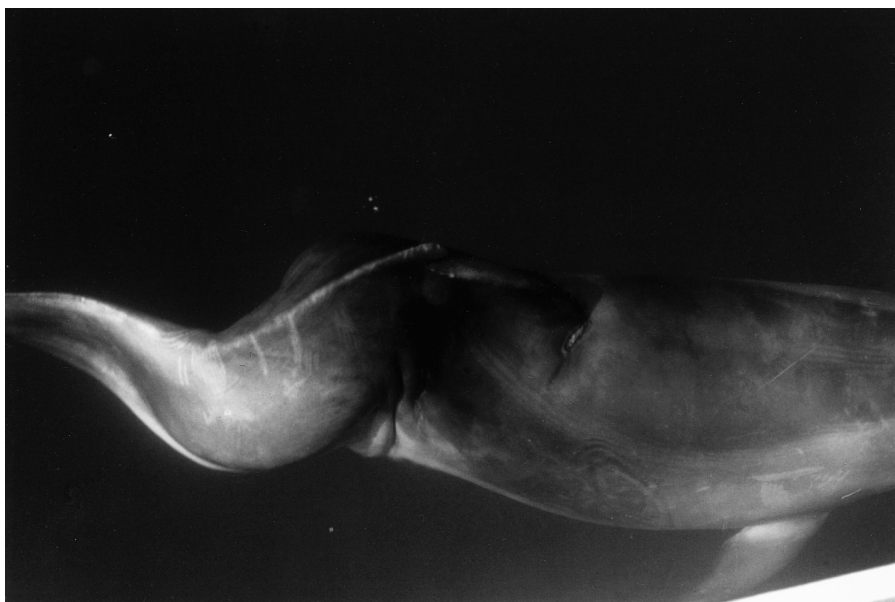
### Results

Case no. 1: 'Quasi' (Catalogue no. 43—J. Berghan) was an adult male bottlenose dolphin with

**Table 1.** Unpublished reports of delphinids with malformations.

Species	Animal name and/or reference no.	Details of animal	Location	Details of malformation	Source
Bottlenose dolphin		Adult male; wild; sighted 28/08/1991	West of Ibiza Island, Balearic Islands, Spain	Kyphoscoliosis—lateral deviation to the left then back to the right, caudal to the dorsal fin. Kyphotic hump directly caudal to the dorsal fin.	L. Silvani, R. Sagarminaga & A. Cañadas, pers. comm., 1996
Bottlenose dolphin		Adult female; wild; sighted 28/08/1991	West of Ibiza Island, Balearic Islands, Spain	Lordosis—horizontal displacement with concavity in caudal region. Vertebral column appeared to be rigid from caudal of the dorsal fin to the peduncle.	L. Silvani, R. Sagarminaga & A. Cañadas, pers. comm., 1996
Bottlenose dolphin	Ayla, MZG IO no. 7579	Female calf; captive born 26/09/1992	Minnesota Zoo, USA	Lordoscoliosis—lateral deviation to the right then back to the left, caudal to the dorsal fin. Indented vertical crease on right lateral surface, slightly caudal to the dorsal fin. Prominent protrusion on the left lateral surface, directly ventral and slightly caudal to the dorsal fin. Dorsal fin leaned to the left. Pronounced horizontal displacement with concavity in lumbocaudal region. Developed slight curvature of the vertebral column several weeks after birth, which progressed with age.	D. M. Fusco, pers. comm., 1996
Bottlenose dolphin	Miai	Juvenile female; captive born 30/10/1989; died 15/08/1992	Windsor Safari Park, UK	Scoliosis—lateral deviation to the left then back to the right, caudal to the dorsal fin. Indented vertical crease directly opposite each lateral convexity caused by the sigmoid curve. Dorsal fin leaned to the left. Born with malformation.	D. C. T. Lindsay, pers. comm., 1996

Bottlenose dolphin	Amber	Adult female; captured from Gulf of Mexico 21/07/1980; died 25/05/1984	Windsor Safari Park, UK	Scoliosis—developed slight lateral deviation to the left then back to the right, caudal to the dorsal fin, overnight. Died approximately seven weeks after malformation developed.	D. C. T. Lindsay, pers. comm., 1996
Bottlenose dolphin	No. AGQ-88-M2	7-yr, 7-mo old male; captive born; died in captivity		Kyphoscoliosis—mild lateral deviation with concavity on left lateral surface. Kyphotic hump centred at T12. Possibly resulted from a compression fracture of a thoracic vertebra.	A. G. Watson, pers. comm., 1996
Common dolphin		Adult; wild; sighted -/11/1996	Alboran Sea	Lordosis—horizontal displacement with concavity in lumbocaudal region.	A. Cañadas, pers. comm., 1997
Killer whale	Humpy, Y Pod no. 10	Calf; wild; sighted 04/11/1995	Tysfjord, Norway	Kyphosis—horizontal displacement with convexity in thoracic region.	F. Ugarte, pers. comm., 1996
Killer whale	Quasimodo, no. N-192	Adult male; wild; sighted 13/11/1992, 18/11/1992, 16/11/1995, 19/11/1995	Tysfjord, Norway	Kyphosis—horizontal displacement with convexity in thoracic region.	F. Ugarte, pers. comm., 1996
Killer whale		Calf (neonate); wild; sighted 08/11/1996	Ofofjord, Norway	Scoliosis—lateral deviation to the left then back to the right, caudal to the dorsal fin. Dorsal fin severed.	F. Ugarte, pers. comm., 1996
Killer whale	No. KB-6	Wild; sighted -/01/1990	Central west coast, Norway	Pronounced protrusion on left dorso-lateral surface, directly caudal to the dorsal fin. Extreme lean of the dorsal fin to the right.	D. Vongraven & A. Bither, pers. comm., 1996




**Figure 1.** Quasi (case no. 1), a bottlenose dolphin with kyphoscoliosis (dorsal view), photographed in the Bay of Islands, NZ. Photo: J. Berghan.



**Figure 2.** Quasi (case no. 1), a bottlenose dolphin with kyphoscoliosis (lateral view), photographed in the Bay of Islands, NZ. Photo: J. Berghan.

kyphoscoliosis, observed in the Bay of Islands (35°14'S 174°08'E) from January 1994 to July 1997. A lateral sigmoid curve, concave to the left, was apparent from directly caudal to the dorsal fin to the peduncle, with a deviation of approximately 30 degrees to the right then approximately 30 degrees

back to the left (Fig. 1). A prominent protrusion was visible on the left lateral surface, slightly caudal to the dorsal fin. When viewed laterally, Quasi had a prominent kyphotic hump directly caudal to his dorsal fin (Fig. 2). Indented vertical creases were apparent on the opposite side to the left lateral



**Figure 3.** Timmy (case no. 2), a juvenile bottlenose dolphin with scoliosis, photographed in the Bay of Islands, NZ, in April 1996. Photo: I. N. Visser.

protrusion and the first sigmoid convexity. Quasi had an open lesion perpendicular and directly cranial to his dorsal fin, surrounded by white tissue. The lesion opened to a depth of approximately 20 mm. The dorsal fin leaned approximately 30 degrees to the right. During the 3-yr, 7-mo period over which Quasi was regularly observed, the malformation appeared to remain unchanged.

Case no. 2: 'Timmy' (Catalogue no. 11—J. Berghan) was a juvenile bottlenose dolphin with scoliosis (Fig. 3). This animal was monitored over a

19-mo period, from September 1994 to April 1996, in the Bay of Islands. At the time of the first observation, Timmy was a neonate, determined by the small size, fetal folds and poor motor skills. A fist-sized protrusion was apparent on the right lateral surface, slightly caudal to the dorsal fin, with a shallow depression on the dorsal surface, directly cranial to the dorsal fin. By December 1994 the protrusion had developed, and in May 1995 the protrusion was conspicuous, with a slight depression cranial and caudal to it. The depression cranial



to the dorsal fin showed a white lesion, approximately 40–50 mm in length, perpendicular to the dorsal fin. By September 1995 the protrusion was prominent, the dorsal fin leaned approximately 30 degrees to the left, and the body axis, from the dorsal fin to the peduncle, appeared to deviate away from the protrusion, curving back to the right. By April 1996 a concave curve had developed on the left lateral surface, preceded by a protruding vertical crease, directly opposite the protrusion. Directly caudal to the protrusion, the vertebral column curvature (as noted in September 1995) was still evident. At this time, the lesion cranial to the dorsal fin appeared as a noticeable round mark. Timmy's malformation gradually progressed during the 19-mo period that observations were made. Although Timmy's mother was sighted in July 1997 and periodically since that time (R. Constantine, pers. comm., 1999), Timmy has not been sighted again and was probably too young to survive independent of its mother.

Case no. 3: 'Scamp' (Catalogue no. 120—J. Berghan) was a sub-adult bottlenose dolphin with a slight lateral malformation, observed in the Bay of Islands on only one occasion, in April 1996. Slight depressions and protrusions were apparent along the animal's lateral surfaces from the dorsal fin to the peduncle, giving the appearance of 'lumpiness'. Two V-shaped notches were apparent along the dorsal surface, one approximately half way from the dorsal fin to the peduncle, and the other directly over the peduncle. These notches appeared to be from line entanglement or propeller cuts.

Case no. 4: 'Squiggles' (Catalogue no. 132—J. Berghan) was a large juvenile bottlenose dolphin with kyphoscoliosis, sighted on only one occasion in the Bay of Islands, in February 1997. Directly caudal to the dorsal fin, a protrusion was visible on the right lateral surface with a concavity on the left lateral surface. When viewed laterally, a prominent kyphotic hump was apparent directly caudal to the dorsal fin. A white lesion was apparent perpendicular and directly cranial to the dorsal fin, which leaned approximately 20 degrees to the left.

Case no. 5: 'Twist' (not catalogued) was a bottlenose dolphin calf with kyphoscoliosis, observed only once in the Bay of Islands, in March 1997. This animal was travelling in close proximity to an adult bottlenose dolphin. A slight lateral sigmoid curve, deviating first to the left then back to the right, was apparent caudal to the dorsal fin. A moderate-sized protrusion was visible on the right lateral surface, directly ventral and slightly caudal to the dorsal fin. When viewed laterally, the calf had a large kyphotic hump directly caudal to the dorsal fin and moderate kyphosis was evident in the cervicothoracic region. An open lesion was evident

perpendicular and directly cranial to the dorsal fin, which leaned approximately 20 degrees to the left.

Case no. 6: 'Quasimodo' (Catalogue no. MN 31—J. Williams & K. Schneider) was an adult male bottlenose dolphin with kyphosis, observed in Doubtful Sound (45°19'S 166°58'E) in November 1995. Two prominent kyphotic humps were apparent along the dorsal surface, the first directly caudal to the dorsal fin, and the second in the caudal region. A deep crease was noticeable at the base of the trailing edge of the dorsal fin. Quasimodo was first recorded in 1991 (Williams 1992), and the malformation appeared to remain unchanged throughout the following eight years (K. Schneider, pers. comm., 2000). This animal's penis was constantly extended, though not fully erect, during the 8-yr period over which he was observed (K. Schneider, pers. comm., 2000).

Case no. 7: 'Marilyn' (Catalogue no. NZ43—I. N. Visser) was an adult female killer whale with slight lordosis, observed on one occasion in March 1996 off Cape Brett, Bay of Islands (35°10'S 174°21'E). When viewed laterally, a shallow concavity was apparent directly caudal to the saddle patch, giving the appearance of a 'sway back' (Fig. 4).

Case no. 8: 'Hollow Head' (Catalogue no. NZ92—I. N. Visser) was an adult female killer whale, observed in the Bay of Islands in September 1996 and May 1997, and at Orewa Beach (36°35'S 174°45'E) and Ruakaka Beach (35°53'S 174°33'E) in October 1999, with slight kyphosis in the cervicothoracic region. This animal had a noticeable depression directly at the blowhole. During the 3-yr period over which observations were made, the malformation appeared to remain unchanged.

Case no. 9: 'Spaghetti' (not catalogued) was a Hector's dolphin calf with scoliosis, observed on three separate occasions in November 1996 near Kaikoura (42°31'S 173°35'E). A lateral sigmoid curve was apparent from directly caudal to the dorsal fin to the peduncle, deviating to the right then back to the left. The animal's right lateral surface had a large protrusion directly ventral to the dorsal fin, with two long indented vertical creases cranial to the protrusion (Fig. 5). The dorsal fin leaned approximately 20 degrees to the left. This dolphin appeared to travel at the same overall speed as the adult that it swam with, but had a 'pulsed' swimming motion, where it appeared to move forward in bursts.

Case no. 10: 'Scolio' (not catalogued) was a juvenile Hector's dolphin with scoliosis, observed in November 1996, and again in September 1999, near Kaikoura. Previously, Scolio had been sighted in the same area, in August 1996 (S. Bräger, pers. comm., 1996). A slight curve of the vertebral



**Figure 4.** Marilyn (case no. 7), a killer whale with slight lordosis, photographed in the Bay of Islands, NZ. Photo: I. N. Visser.



**Figure 5.** Spaghetti (case no. 9), a Hector's dolphin calf with scoliosis, photographed near Kaikoura, NZ. Photo: I. N. Visser.

column, deviating to the right then back to the left, was apparent caudal to the dorsal fin. A protrusion was visible on the right lateral surface, slightly caudal to the dorsal fin. The dorsal fin leaned

approximately ten degrees to the left. During the 2-yr, 10-mo period over which observations were made, the malformation appeared to remain unchanged.

### Discussion

Four bottlenose dolphins with scoliosis or kyphoscoliosis presented here (case nos 1, 2, 4 and 5) each had a noticeable lesion directly cranial to the dorsal fin, which could be an external manifestation of the vertebral column malformation. However, this was not apparent with the two Hector's dolphins (case nos 9 and 10).

Nine cases involving scoliosis and/or a lateral protrusion specify the angle of the dorsal fin, seven of which show a deflection away from the lateral protrusion (case nos 1, 2, 4, 5, 9 and 10; Table 1, no. KB-6). In contrast, one case (Table 1, 'Ayla') showed a dorsal fin deflection toward the lateral protrusion. This is the only case of lordoscoliosis. The remaining case (Table 1, 'Miai') did not show a lateral protrusion, however, the dorsal fin leaned toward the scoliotic convexity. These dorsal fin deflections possibly compensate for a displaced centre of gravity caused by the lateral protrusion or scoliotic convexity.

The longevity of delphinids with vertebral column malformations is largely unknown. However, it would seem that at least some animals are able to survive well into adulthood, as in the case of a male bottlenose dolphin in Sarasota Bay, Florida, who has been observed for the past 20-yr with scoliosis in the caudal peduncle region (R. S. Wells, pers. comm., 2000). In the cases of opportunistic observations of free-ranging delphinids presented here, neither the longevity of the malformation nor the fate of the animal can be determined. Nonetheless, observations have been made for periods of up to 8-yr (see case no. 6). A range of delphinid species, age classes, gender, and severity of malformation are presented here, yet all appeared to be in good physical health and able to function independent of their malformation. The one exception may be 'Amber' (see Table 1), who developed a malformation overnight and died approximately seven weeks later. However, it is unknown to the authors as to whether or not this was a result of the malformation. It is likely that the longevity of delphinids with vertebral column malformations depends largely on the extent and resulting complications of the malformation.

We are unable to determine the cause of these malformations, however previously documented cases of vertebral column malformation in cetaceans have been associated with a diverse range of causative factors. Physical abnormalities, including vertebral column malformations, in beluga whales from St. Lawrence Estuary, Canada, were tentatively linked to high levels of organochlorines found in the tissues of these animals (Johnston & McCrea, 1992). Another documented cause of malformation in cetaceans relates to stress or exertion, known as

exertional rhabdomyolysis, and is considered 'a potentially fatal condition associated with the capture or transportation of wildlife' (Colgrove, 1978). Bartsch *et al.* (1977) reported that the syndrome ensues after physical exertion, stress, or capture and is characterized by muscle necrosis and myoglobinuria. Vertebral column malformation forming subsequent to transportation has been documented for a common dolphin (Clokier & Kobus, 1990). Malformation may also be caused by spondylodiscitis or spondylo-osteomyelitis, as the result of a bacterial infection (Kompanje, 1995a), often following trauma. Cases have been reported in a bottlenose dolphin (Alexander *et al.*, 1989), and killer whales (Kompanje, 1995c). However, trauma-induced (e.g., boat strike, interspecific or conspecific aggression) vertebral column deviations may occur without infectious spondylitis (E. J. O. Kompanje, pers. comm., 1999), e.g., a bottlenose dolphin (E. J. O. Kompanje, pers. comm., 1999) and possibly a Risso's dolphin (Nutman & Kirk, 1988). Congenital malformations occur due to abnormalities of vertebral development (Weinstein, 1995; Winter, 1995) and were reported for a fin whale fetus (Slijper, 1949) and a tucuxi (Fragoso, 1998) and suggested for a white-beaked dolphin (Kompanje, 1995b). As there are over 150 syndromes and diseases in which scoliosis may play a part in mankind (Robin, 1990), it is likely that the conditions mentioned here are only a few of those which play a causative role in vertebral column malformations in cetaceans.

### Acknowledgments

Thanks to A. Bisther, A. Bortolotto, S. Bräger, A. Cañadas, L. Clokier-van Zyl, J. M. Dixon, D. M. Fusco, D. C. T. Lindsay, R. Sagarminaga, K. Schneider, F. Ugarte, A. M. van Ginneken, D. Vongraven, A. G. Watson, R. W. Wells, J. Williams and B. Wilson who all contributed valuable information on published and unpublished accounts of malformed cetaceans. Our immense gratitude to E. J. O. Kompanje for providing valuable literature, and improving an earlier draft of this manuscript with his comments and suggestions. Thanks also to R. Constantine and B. Wilson for offering helpful comments on an earlier draft. Reviews by A. G. Watson and G. Lacave further improved this manuscript. INV's research was supported by Adopt an Orca NZ.

### Literature Cited

- Alexander, J. W., Solangi, M. A. & Riegel, L. S. (1989) Vertebral osteomyelitis and suspected diskospondylitis in an Atlantic bottlenose dolphin (*Tursiops truncatus*). *Journal of Wildlife Diseases* **25**, 118–121.



- Bartsch, R. C., McConnell, E. E., Imes, G. D. & Schmidt, J. M. (1977) A review of exertional rhabdomyolysis in wild and domestic animals and man. *Veterinary Pathology* **14**, 314–324.
- Berzin, A. A. (1971) *The Sperm Whale (kashalot)*, p. 273. Izdatel'stvo 'Pishchevaya Promyshlennost', Moskva.
- Israel Program for Scientific Translations: Jerusalem 1972.
- Bortolotto, A. (1996) 'Orso'—Grampo, *Grampus griseus*, (G. Cuvier, 1812). Intervento di soccorso su un esemplare spiaggiato. Technical report (in Italian) for Fondazione Cetacea: Milano, 17 pp.
- Clokier, L. & Kobus, R. (1990) White muscle disease in a stranded common dolphin. Paper presented at the Proceedings of the 18th Conference of the International Marine Animal Trainers Association, Chicago, Illinois, November 4–9, 1990.
- Colgrove, G. S. (1978) Suspected transportation-associated myopathy in a dolphin. *Journal of the American Veterinary Medicine Association* **173**, 1121–1123.
- Dawson, S. & Slooten, L. (1996) *Down-under Dolphins*, 54 pp. Canterbury University Press: Christchurch, New Zealand.
- Dixon, J. M. (1984) Hepatitis and bone lesions in a stranded juvenile common dolphin *Delphinus delphis* Linnaeus. *Australian Mammalogy* **7**, 225–228.
- Fragoso, A. B. L. (1998) Bone anomalies of marine tucuxi dolphin *Sotalia fluviatilis* of Rio de Janeiro Coast, Brazil. The World Marine Mammal Science Conference (Abstracts), Monaco 20–24 January, 1998.
- Johnston, P. & McCrea, I. (1992) *Death in Small Doses—the effects of organochlorines on aquatic ecosystems*, 19 pp. Greenpeace International: Netherlands.
- Kompanje, E. J. O. (1995a) Differences between spondylo-osteomyelitis and spondylosis deformans in small odontocetes based on museum material. *Aquatic Mammals* **21**, 199–203.
- Kompanje, E. J. O. (1995b) On the occurrence of spondylosis deformans in white-beaked dolphins (*Lagenorhynchus albirostris* Gray, 1846) stranded on the Dutch coast. *Zoologische Mededelingen Leiden* **69**, 231–250.
- Kompanje, E. J. O. (1995c) Strandings of killer whales (*Orcinus orca*) in the Netherlands between 1783 and 1995 with some remarks on skeletal and dental pathology (Mammalia, Cetacea, Odontoceti). *Deinsea* **2**, 67–82.
- Lilley, J. C. (1961) *Man and Dolphin—adventures on a new scientific frontier*, 81 pp. Double Day Publishers: New York.
- Miller, B. F. & Brackman Keane, C. (1983) *Encyclopedia and Dictionary of Medicine, Nursing, and Allied Health*, third edition. W. B. Saunders Company: Pennsylvania.
- Nutman, A. W. & Kirk, E. J. (1988) Abnormalities in the axial skeleton of a Risso's dolphin, *Grampus griseus*. *New Zealand Veterinary Journal* **36**, 91–92.
- Osmond, M. G. & Kaufman, G. D. (1998) A heavily parasitized humpback whale (*Megaptera novaeangliae*). *Marine Mammal Science* **14**, 146–149.
- Robin, G. C. (1990) *The Aetiology of Idiopathic Scoliosis—a review of a century of research*, 19 pp. CRC Press, Inc.: Florida.
- Slijper, E. J. (1949) Pregnancy and parturition of the cetacea. *Bijdragen tot de Dierkunde* **28**, 416–448.
- Weinstein, S. L. (1995) Deformities of the spine. In: J. N. Weinstein, B. L. Rydevik & V. K. H. Sonntag (eds.) *Essentials of the Spine*, pp. 195–230. Raven Press: New York.
- Wells, R. S. & Scott, M. D. (1997) Seasonal incidence of boat strikes on bottlenose dolphins near Sarasota, Florida. *Marine Mammal Science* **13**, 475–480.
- Williams, J. A. (1992) The abundance and distribution of bottlenose dolphins (*Tursiops truncatus*) in Doubtful Sound, 58 pp. M.Sc. Thesis, University of Otago, New Zealand.
- Wilson, B., Thompson, P. M. & Hammond, P. S. (1997) Skin lesions and physical deformities in bottlenose dolphins in the Moray Firth; population prevalence and age-sex differences. *AMBIO* **26**, 243–247.
- Winter, R. B. (1995) Congenital spinal deformity. In: *Moe's Textbook of Scoliosis and Other Spinal Deformities*, third edition, pp. 257–294. W. B. Saunders Company: Pennsylvania.
- Wise, L. D., Beck, S. L., Beltrame, D., Beyer, B. K., Chahoud, I., Clark, R. L., Clark, R., Druga, A. M., Feuston, M. H., Guittin, P., Henwood, S. M., Kimmel, C. A., Lindstrom, P., Palmer, A. K., Petrere, J. A., Solomon, H. M., Yasuda, M. & York, R. G. (1997) Terminology of developmental abnormalities in common laboratory mammals (version 1). *Teratology* **55**, 249–292.